

Medical record form with fields for Name, Age, Sex, and a barcode.

OPR-6 PREMISES form with handwritten registration number 45-124097 and date of birth.

DIPG

Treatment

efo/w Di Anjali VR

Plan:- Radical RT 60Gy/30 #/6 wk

Ad.

- RT ward admission for supportive care.
- To start promethazine on Monday on 21/8/23.
- To start low dose steroid on tapering dose.

Handwritten signature

167

RISHNA .

आयु AGE: 7 years

लिंग/SEX: M

पता संख्या H.NO: VILL ANDANI  
र/प्रखण्ड CITY/BLOCK: DISTRICT MAINPURI  
राज्य STATE: UTTAR PRADESH  
मोबाइल MOBILE NO:  
रिश्ता: FATHER

गली / गृहल्ला STREET/MOH:  
पिन PIN:  
दूरभाष सं. PHONE NO:  
स्थान Location: Paediatrics Emergency  
Criticality: Red / Yellow / Green

HR	BP	mmHg RR	/min	spO2	%
16	99/56	110	2	98	

in/ New Emergency  
 Δ- DIPC  
 Now come = progressive weakness &  
 ↓ oral acceptance  
 ↓ speech output  
 ↓ Nix flup → rife for Radiation

ABCDE) : Assessment Pentagon

Circulation HR: 98 → 110 bpm CFT: 2 BP: 99/56 mmHg Peripheral pulse: Poor/Good Central pulse: Poor/Good Skin temp: Warm/cool Others:	Disability GCS: E3V3M5 Pupil size: 3 /min Pupillary Reactions: RTL Motor activity: Normal & Symmetrical/Asymmetrical/ Posturing/Flaccidity/Seizure Blood Sugar: .....mg/dl Exposure: Temp: 36.5 Colour: Normal/pallor/cyanosis/mottled Any other skin lesions:
---	--

Diffuse pontine glioma, → NO +/- OTC/ICP.

Adv. NG insert f/b N.G @ 120ml @ 2H.  
200ml @ 3H

AC 10.1 - Radiotherapy Opinion (Informed)  
Dry Emesis 4mg IV stat

33



डा. बी. आर. अम्बेडकर संस्थान रोटरी कैंसर अस्पताल  
Dr. B.R. Ambedkar Institute Rotary Cancer Hospital  
अ.भा.आ.स. अस्पताल/A.I.I.M.S. HOSPITAL  
बहिरंग रोगी विभाग/Out Patient Department  
अस्पताल के अन्दर धूम्रपान करना है।/SMOKING PROHIBITED IN HOSPITAL PREMISES

OPR-6

RT-12409T

एम्ब/Unit PROF. DR. B. GUPTA  
विभाग/Dept

IRCH No. \_\_\_\_\_

संस्थागत संकेतित No./O.P.D. Regn. No.

OP Ticket

दि./मा/वर्ष /M/D of	लिंग Sex	वय Age	जन्म तिथि/Date of Birth

IRCH No. JR2527  
Unit Name: Radiotherapy Clinic  
Dept. RADIATION ONCOLOGY  
Central

Reg. Date: 19/03/23  
Clinic No. 20230298  
UHID: 109944181

नाम  
Name KRISHNA  
S/O. RAJUL KUMAR  
Phone No. 9528339001  
Address VILL. ANDANI, DISTRICT MAINPURI, UTTAR PRADESH,  
INDIA

Sex/Age M/27

Room: Grand Room (Shift Morning)  
District: MAINPURI, UTTAR PRADESH.

उपचार/Treatment

The patient is planned for radical RT of 60Gy/30 Fr/6wks  
to four using 0/L lateral neck fields using BID technique  
with 6MV photon energy

Adv -

1. RT requirement 27Gy - (2) → (28)

2. Avoid application of oil/creams/steam over irradiated area.

3. continue treatment in RT ward

फि-750/9/20585

24/8 → 26/8  
27/8 → 28/8  
29/8 → 29/8  
30/8 → 29/8  
31/8 → 29/8  
01/9 → 29/8

4/9 → 29/8  
5/9 → 30/8  
6/9 → 30/8  
8/9 → 30/8  
11/9 → 30/8  
12/9 → 30/8

15/9 - 30/8

Amudya  
JRD

अंगदान-जीवन का बहुमूल्य उपहार/ORGAN DONATION - A GIFT OF LIFE

O.R.B.O., AIIMS, 26588360, 26593444, www.orbo.org Helpline - 1060 (24 hrs service)

बाहर से आने वाले रोगियों के लिए धर्मशाला की सुविधा उपलब्ध है/Dharamshala facility is available for outstation patient

16/9 → 31/8  
16/9 → 31/8

08/09/23

- completed 246y/12# of RT
- ~~no fresh c/o~~ - constipation x ~4d

no CBC | LFT | RFT UA

Adv. - 1. cont RT

2. R/V weekly c CBC | LFT | RFT

3. syp (amoxicillin 216cp OD HS x 5days) → OD alternate day

Srinidya  
JR/RO

1/09/2023

- completed 266y/13# of RT
- constipation - unobated

14/9/23

Adv. 1. ~~no~~ 2 dose 21cp PO-PR (10ml)

↓  
Continue RT Supra

Adv. - 1. cont RT

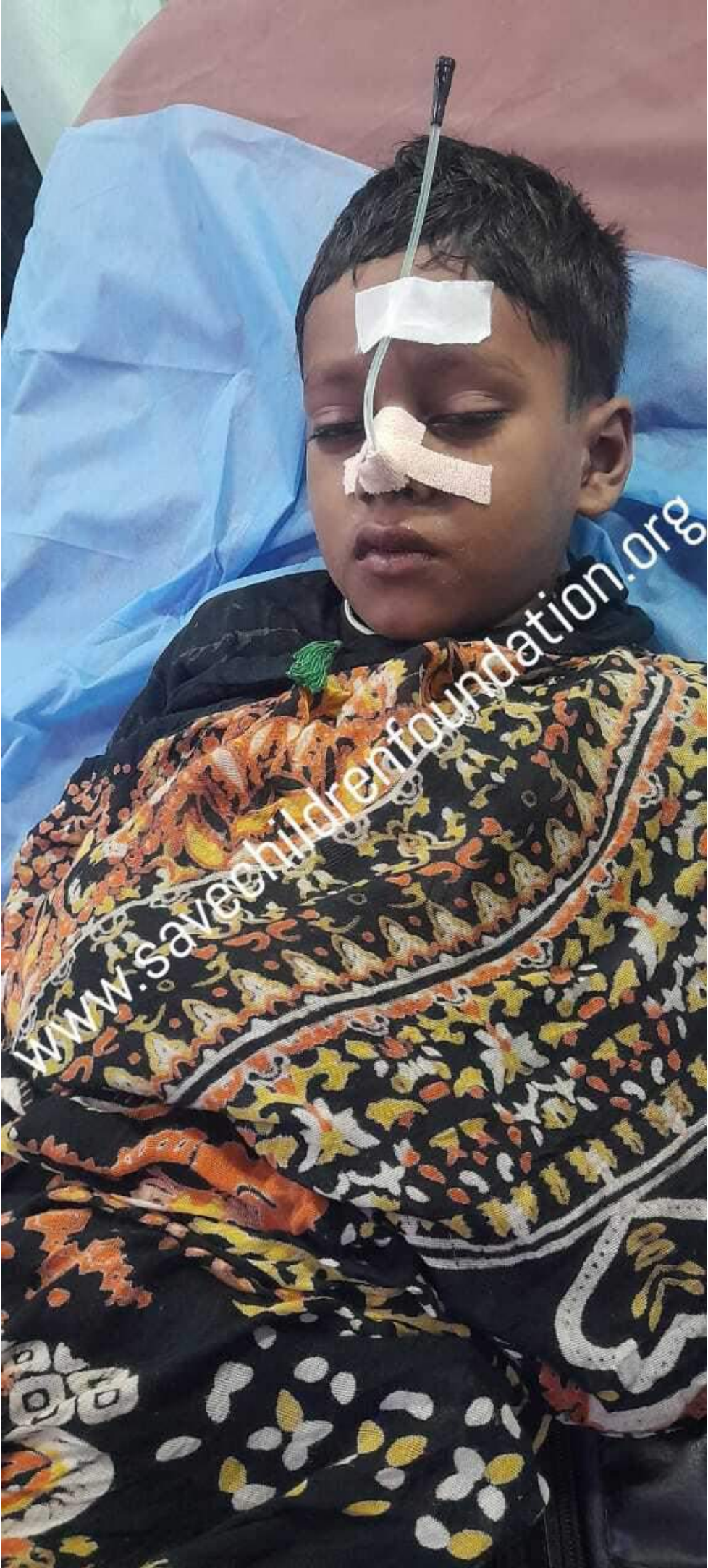2. P/R <sup>pediatric</sup> <sub>enema</sub> 3 dose - stat

3. cont (amoxicillin) syp

4. R/V weekly c CBC | LFT | RFT

Srinidya  
JR/RO

www.savechildrenfoundation.org





PT. NAME - KRISHNA

07 YEARS/M

DATE - 31.07.2023

REF. BY - DR. NARESH SHARMA, MD, DM.

### MRI BRAIN WITH CONTRAST AND SPECTROSCOPY

TECHNIQUE: MRI SPECTROSCOPY WAS DONE USING FOLLOWING SEQUENCES ON 32 CHANNEL SIEMENS AVANTO-

- AXIAL T1 & T2 WEIGHTED & FLAIR
- SAGITTAL T2 WEIGHTED,
- CORONAL T2 WEIGHTED,
- DIFFUSION WEIGHTED IMAGING,

*Motion artifacts are noted due to uncooperative patient.*

An intraaxial ill-defined T2 / FLAIR hyperintense lesion measuring 5.5 x 3.3 x 4.6 cm is seen in posterior fossa in mid brain & pons with an exophytic component extending in right cerebellopontine angle and cerebellopontine cisterns causing marked mass effect over right cerebellar hemisphere and medulla. Intratumoral cyst is noted measuring 2.1 x 1.8 cm. The lesion is appearing iso to hypointense on T1W images with subtle diffusion restriction and minimal blooming on GRE images appearing bright on phase images, suggestive of hemorrhage. On post contrast images there is heterogeneous enhancement of the cyst wall and solid portion of the lesion.

The lesion is closely abutting the right vertebral artery and basilar artery which however show maintained flow voids.

Mild perilesional edema is seen in mid brain & pons.

The fourth ventricle is also partially effaced with prominence of both lateral ventricles and mild periventricular CSF ooze.

Multivoxel spectroscopy was performed over the enhancing part of lesion. Elevated choline peak is seen. The choline: Creatinine ratio is 2.8 & choline: NAA ratio is 1.2. No abnormal lactate / lipid peak is seen.

*Findings are suggestive of primary mitotic pathology, likely focal dorsally exophytic brain stem glioma. In view of marked choline peak and increased choline - Creatinine ratio & choline - NAA ratio possibility of high grade glioma is more likely.*

The study reveals normal signal intensity of rest of the brain parenchyma. Basal ganglia shows normal signal intensity.

Cervico-medullary junction is normal.  
Paranasal sinuses are clear.

### - Please Correlate Clinically.

Dr. Anshu Ahluwalia  
DNB - MNAMS  
Senior Radiologist

Dr. Amit Singhal  
MBBS, MD  
Consultant Radiologist

Dr. Shubhangi Sharma  
MBBS, MD, DNB  
Consultant Radiologist

Dr. Neelam Sharma  
MBBS, DNB, MNAMS  
Consultant Radiologist  
Fellow Abdominal Radiology  
(AIMS Jodhpur)

Dr. Saanichi Mahinderu  
MBBS, DNB  
Consultant Radiologist  
Former SR at J. J. Hospital/Mumbai

Dr. Shiv Mahinderu  
MBBS, M.D. DNB  
Consultant Radiologist  
Former Asst. Prof. of Radiology at  
Grant Medical College, Mumbai

Dr. Pankaj M  
M.D.  
CAMS in Diag. I  
University of Vient  
Consultant I

Tests have technical limitations. Collaborative clinicopathological interpretation is mandatory. In case of disparity test may be repeated immediately.

Home collection of sample Contact No. :

Sadar : 70880 90001

Argil : 70885 81111

Ajpur : 70554 00054, 94122 62032

Athura : 94100 38913



AMBULANCE SERVICE  
FOR CT & MRI  
\*CT - 70886 10001  
82731 39433  
\*MRI - 70885 10001



NOT VALID FOR MEDICOS LEGAL

## RADIOLOGY UNIT

Dr. B. R. Ambedkar Institute Rotary Cancer Hospital  
All India Institute of Medical Sciences, New Delhi-110029

Patient Name: Master, Krishna K.	Age/Gender: 7 Years and 0 Mo
Patient UHID : 106944181	IRCH No : 302527
Accession No : 1291639	Location : RT WARD (1st Floor)
Date of Examination : 22-AUG-2023 10:32 AM	

**Procedure:** Ultrasound of Kidneys, Ureters and Urinary bladder.

Clinical background: DIPG.

Right Kidney: Normal size (7.2 cm) and echotexture. No hydronephrosis/ calculus.

Left Kidney: Normal size (7.5 cm) and echotexture. No hydronephrosis/calculus.

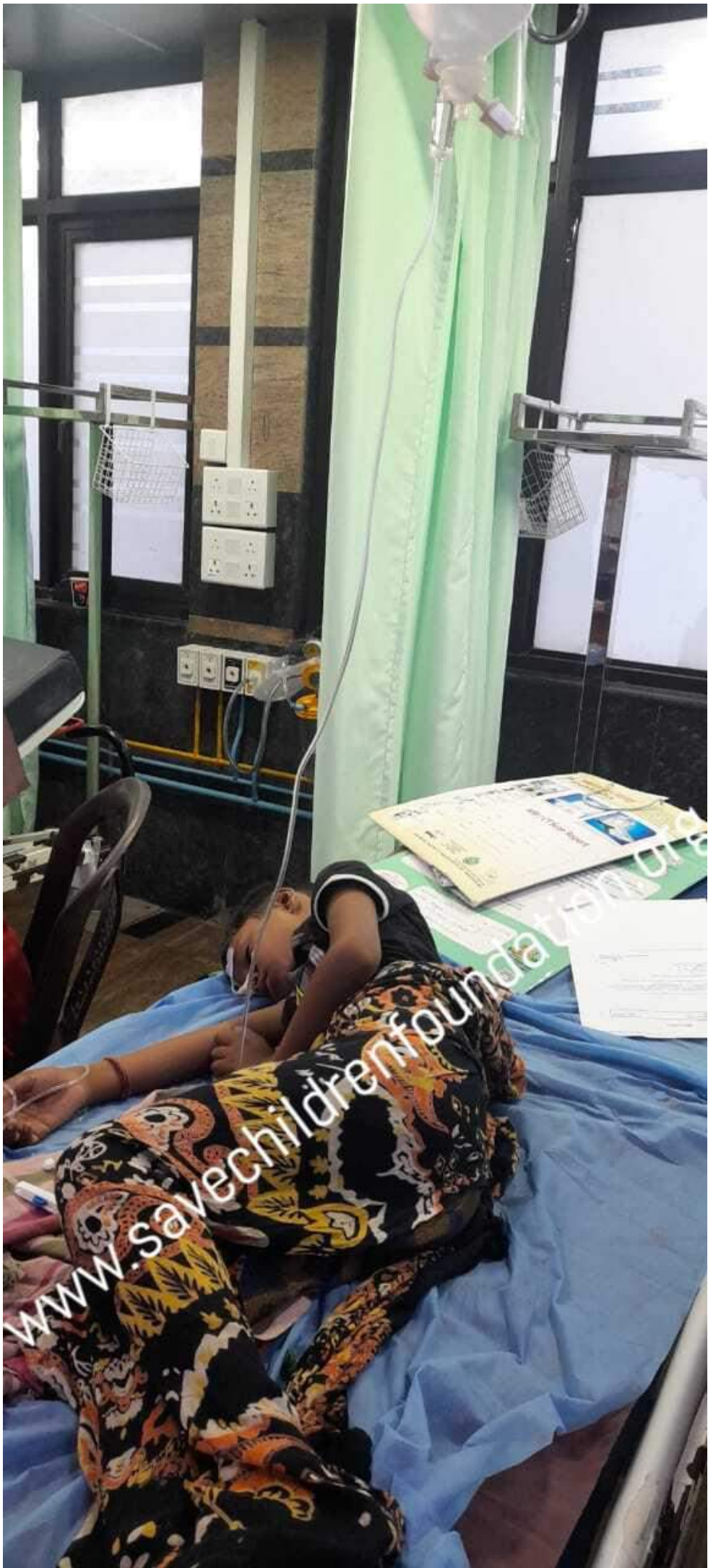
Ureters are not dilated.

Urinary bladder: Free floating echoes ? cystitis.

**Impression:** ? Cystitis.

**Advise:** Urinal R/M and culture.

**Radiologist:** / Dr. Yashaswi Singh (JR)



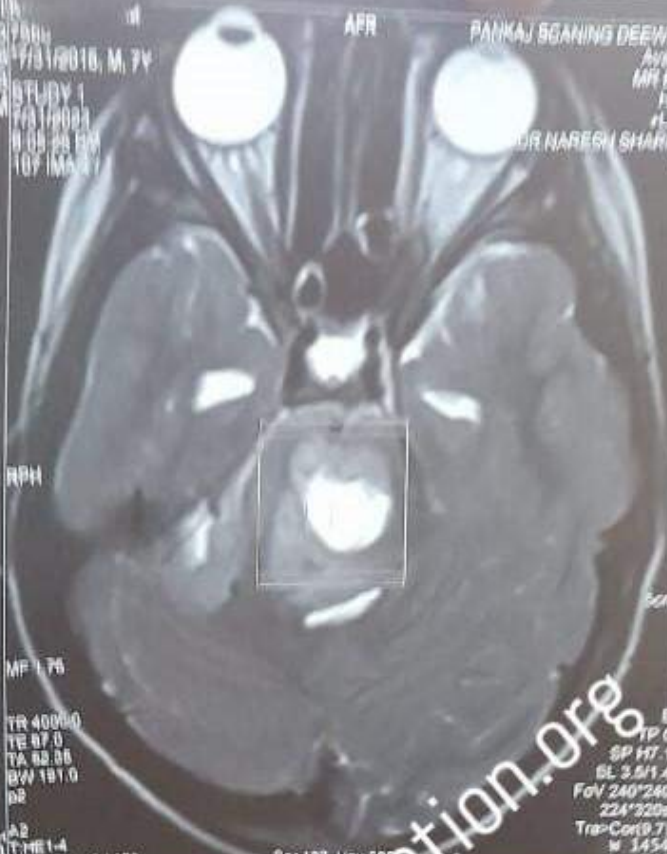
[www.savechildrenfoundation.org](http://www.savechildrenfoundation.org)



PANKAJ SCANNING DEEWANI  
Avanto 7600  
MR B19 7/31/2016, M, 7Y  
7/31/2016  
8:21:20 PM  
STUDY 1  
7/31/2016  
8:08:29 AM  
107 IMA 11 / 1

AFR

PANKAJ SCANNING DEEWANI KRISHNA  
Avanto 7600  
MR B19 7/31/2016  
7/31/2016  
8:21:20 PM  
DR NARESH SHARMA



RPH

MF 1.76

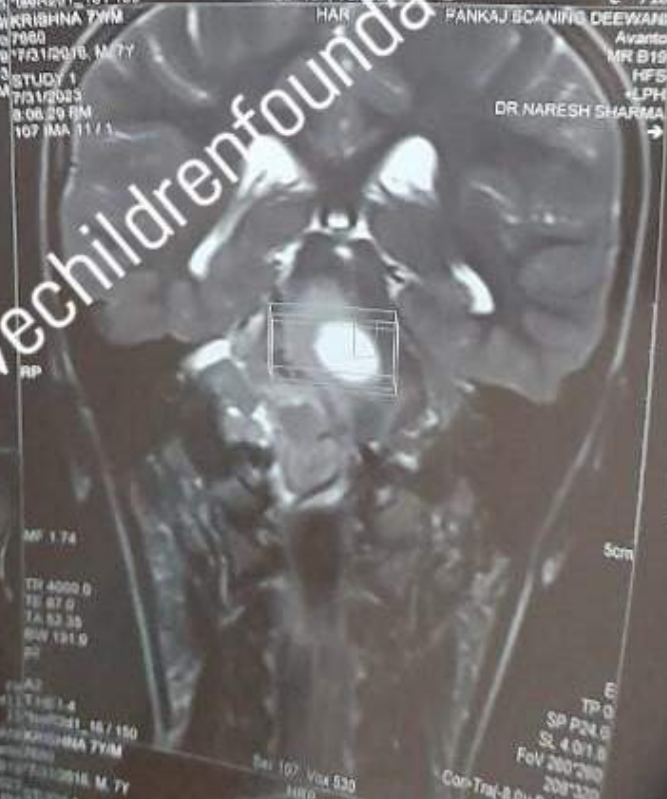TR 4000.0  
TE 87.0  
TA 82.35  
BW 191.0  
D2

TP 0  
SP 17.1  
SL 3.014  
FoV 240\*240  
224\*220  
Traj-Cor 9.71° Cor\_Sel 1  
w 1454 TR 1000  
C 716 MA 4 / 74

VOL AP LR PA2  
P35 P21 5 5  
S12E  
PANKAJ SCANNING DEEWANI KRISHNA TVM  
Avanto 7600  
MR B19 7/31/2016, M, 7Y  
7/31/2016  
8:21:20 PM  
STUDY 1  
7/31/2016  
8:08:29 AM  
107 IMA 11 / 1

Ser.107, Vol.52

PANKAJ SCANNING DEEWANI KRISHNA  
Avanto 7600  
MR B19 7/31/2016  
7/31/2016  
8:21:20 PM  
DR NARESH SHARMA



RP

MF 1.74

TR 4000.0  
TE 87.0  
TA 82.35  
BW 191.0  
D2

TP 0  
SP 24.8  
SL 4.018  
FoV 280\*280  
208\*320  
Cor-Traj -8.01° Sag-1.1° Cor\_Sel 1  
w 1454 TR 1000  
C 875 MA 4 / 74

VOL AP LR PA2  
P35 P21 5 5  
S12E  
PANKAJ SCANNING DEEWANI KRISHNA TVM  
Avanto 7600  
MR B19 7/31/2016, M, 7Y  
7/31/2016  
8:21:20 PM  
STUDY 1  
7/31/2016  
8:08:29 AM  
107 IMA 11 / 1

Ser.107, Vol.53

PANKAJ SCANNING DEEWANI KRISHNA  
Avanto 7600  
MR B19 7/31/2016  
7/31/2016  
8:21:20 PM  
DR NARESH SHARMA

www.savechildrenfoundation.org

नाम Master Krishna

उम्र Age 74  
सर्विस Service M.

दिनांक Date 17/8/23

युग्म सं. नं. UHID No. 1069441

ज्योतिष पुरो  
Professor IC

Notes written by

CLINICAL NOTES

18/8/23  
Thanks for Referral.  
C/S/B SR On Call Road. Duro.

c/o DIPG.

MRI brain on 31/7/23.

- Ill defined lesion 5.6 x 3.1 x 4.6 cm. seen in posterior in mid brain & pine with an exophytic component extending in Rt. cerebellopontine angle & prepontine cistern.

c/o progressive weakness. x 3 days.

decreased oral intake. x 3 days.

S/E: → E3, S15. SpO2 - 98% on room air.  
→ Patient is not registered & IRCH, not registered Radiation Oncology

Adv: → Continue Symptomatic Treatment.  
NG tube insertion & NG feeds.

To review in IRCH screening OPD tomorrow.  
IRCH registration & registration & NOC Boardroom

UP Panchini gl